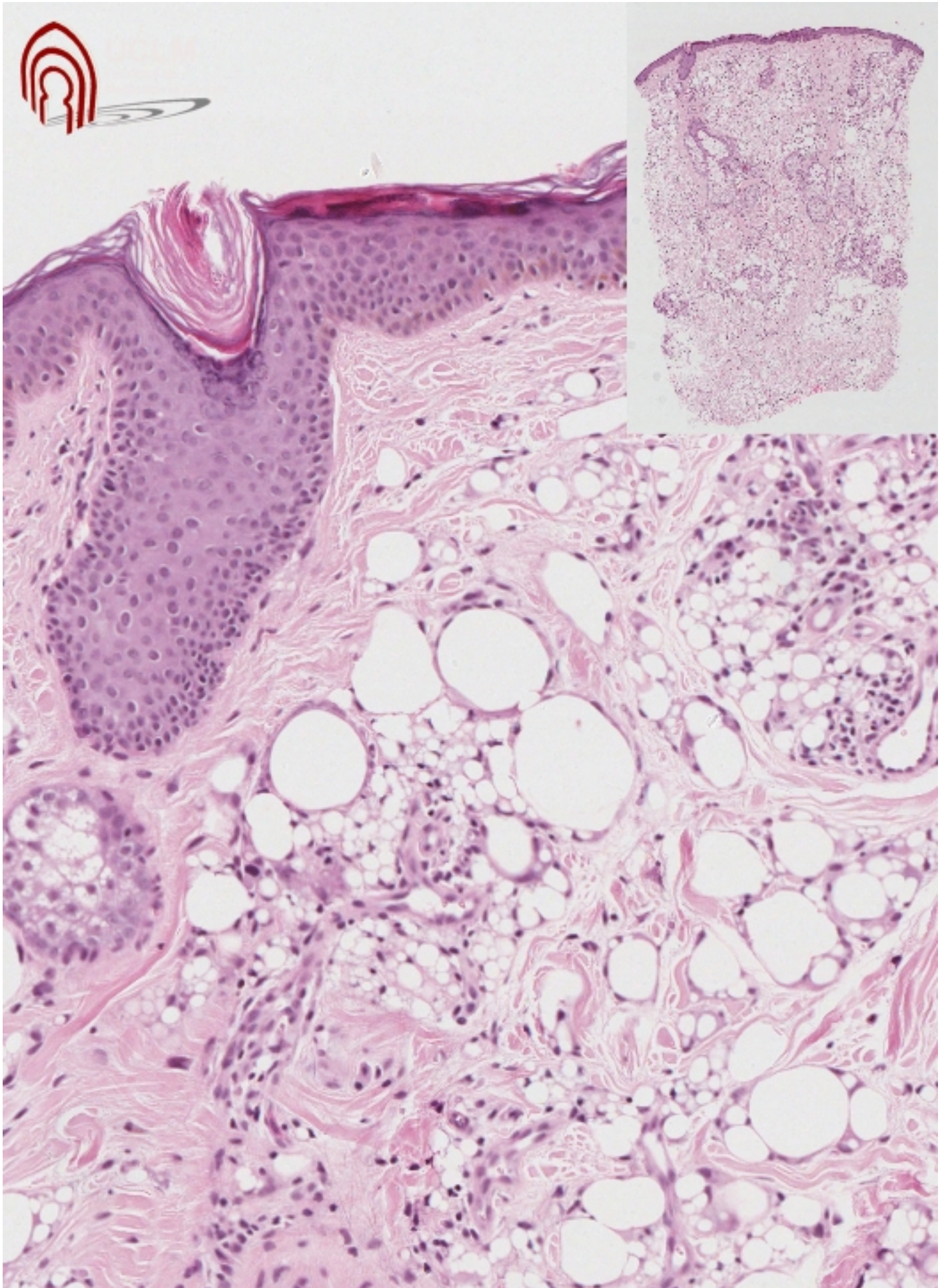


There are no translations available.



Reacción a cuerpo extraño.

Tuesday, 12 May 2015 07:54 - Last Updated Monday, 25 May 2015 13:44

DESCRIPCIÓN ANATOMOPATOLÓGICA: Case in Dermatology Macrophages and multinucleated giant cells fagocitando depósitos de